

## Curriculum Vitae



### Personal Information

- Name: saman mohammadipour
- Date of birth: 10 June 1978
- Sex: male
- Religion: Iran/Tehran
- Mobile: 00989121541941
- [samanmp@yahoo.com](mailto:samanmp@yahoo.com)

## **Educational Background**

- General medicine Azad university of Tehran 1996- 2003
- General surgery Tehran university of medical science (tums) 2007-2011
- Board of surgery 2011
- FELLOW OF COLORECTAL SURGERY (Iran university of medical science) 2014

## **Educational workshop:**

- Basic laparoscopy training certification, Tehran university, 2010  
<http://www.laparoscopytraining.ir/participating.aspx>
- Skin care and monotherapy, certification, 2010
- Wound management training 2009
- Workshop of fast sonography TUMS. 2011
- Research and writing article workshop 2008

## **International workshop:**

- **BERLIN, the 6th International NPWT Expert Meeting to be held in Berlin, Germany on 20th – 21st March 2015.**
- **ISTANBUL, train the trainee, advanced laparoscopic training, covidien corporation 2-3 June 2015**
- **SHARJAH, surgical institute ,university of Sharjah, product safety training and workshop advance colorectal surgery course , 5<sup>th</sup> and 6<sup>th</sup> January 2017**

## **Working background**

- Principle of KHodabandeh health network ....Garmab medical center AS A GP 2003-2007
- Scientific responsible for site [WWW.LAPSURGE.IR](http://WWW.LAPSURGE.IR) 2007-2010
- Cooperation with Jalal Ara company in Iran (Smith & Nephew)
- Fereidonshar(Esfahan) rasool hospital as a surgeon 2011-2012

- Scientific responsible for [www.ircps.com](http://www.ircps.com)
- Medical consultant of pezeshki.net  
[http://pezeshki.net/index.php?option=com\\_content&view=article&id=2776:%D8%AF%DA%A9%D8%AA%D8%B1-%D8%B3%D8%A7%D9%85%D8%A7%D9%86-%D9%85%D8%AD%D9%85%D8%AF%DB%8C-%D9%BE%D9%88%D8%B1&catid=237&Itemid=197](http://pezeshki.net/index.php?option=com_content&view=article&id=2776:%D8%AF%DA%A9%D8%AA%D8%B1-%D8%B3%D8%A7%D9%85%D8%A7%D9%86-%D9%85%D8%AD%D9%85%D8%AF%DB%8C-%D9%BE%D9%88%D8%B1&catid=237&Itemid=197).
- Committee board of IRCPS (coloproctology society) 2014 TILL NOW
- Committee board OF ICS (IRANIAN CONTINENCE SOCIETY) 2013 TILL NOW

### **Clinical Experiences**

- Colon and rectal surgery  
 Abdominal approach for conditions such as cancer, Polyp, FAP, Ulcerative Colitis, Prolapse, Pouch  
 Anorectal surgery  
 Hemorrhoids, Fissure, Fistula, Solitary Rectal Ulcer
- General Surgery  
 Abdominal, Head and Neck, Breast, Trauma
- Endoscopic Procedures Diagnostic & Therapeutic
- Electrophysiologic study of anal canal, EMG. N.C.V. Manometry
- Intrarectal Sonography

### **Memberships**

- Iranian continence society
- iranian society of colon and rectal surgeons(ircps)
- International university of colon and rectal surgeons
- Iranian college of surgeons

### **Academic Positions**

1. Fellow of colorectal surgery, faculty of Iran University of medical science 2015
2. Fellow of colorectal surgery, faculty of Islamic Azad University Medical Branch of Tehran 2016

## **International Lectures**

- **TM's 1st World Virology & Microbiology Online Conference April 19-21, 2012**

**9:30 – 10:00 AM Presentation Title: Use of Negative Pressure Wound Therapy With Silver Base Dressing for Necrotizing Fasciitis. Saman Mohammadi Pour, Tehran University of Medical Sciences, Tehran, Iran.(www.targetmeeting.com)**

- **“CORRELATION BETWEEN ESR AND CRP WITH EARLY FAILURE OF ARTERIOVENOUS FISTULA”**

**7th International Congress of the Vascular Access Society, Istanbul – Turkey, May 5-7, 2011**

**J Vasc Access :2011 122137181 with oral presentation**

## **Local lectures**

- **“TWO TYPE SYNCHRONOUS COLONIC ADENOCARCINOMA WITH APPENDICEAL Carcinoid” Farsi oral presentation 2010, Tehran University (tums)**
- **“ wound management in cancer “ Farsi oral presentation , Iranian association of general surgeon ,2010 (<http://iags.ir/5congress.php>)**
- **Isfahan university HTN control conference ۲۰۱۳**
- **Isfahan university most emergent hospital cases 2013**
- **Isfahan University writing death certification 2013**
- **Isfahan University diabetes and complication 2013**
- **WORKSHOP OF BULKING AGENT IN ANAL INCONTINENCE, IUMS, MARCH 2014**
- **Anal fistula , annual congress of coloproctology 2014**
- **Work shop of hemorrhoid and complication , IUMS 2014**

- Forensic medicine , anal rape and sex , 2015
- Constipation , shariati hospital , gastrointestinal society , 2015
- Anal fistula , Iranian association of surgeons (IRAOS) 2015
- Anal benign diseases , talaghani hospital , 2015
- Pelvic floor physiotherapy ,Iran rehabilitation university , 2015
- Annual congress of cancer , imam Khomeini hospital , 2015,2016

**Publication in English :**

- **Pub Use of Negative Pressure Wound Therapy With Silver Base Dressing for Necrotizing Fasciitis”**  
Copyright © 2011. Wound, Ostomy and Continence Nurses Society journals.lww.com  
[http://journals.lww.com/jwocnonline/Abstract/2011/07000/Use\\_of\\_Negative\\_Pressure\\_Wound\\_Therapy\\_With\\_Silver.21.aspx](http://journals.lww.com/jwocnonline/Abstract/2011/07000/Use_of_Negative_Pressure_Wound_Therapy_With_Silver.21.aspx)
- **CORRELATION BETWEEN ESR AND CRP WITH EARLY FAILURE OF ARTERIOVENOUS FISTULA.(abstract).** 7th International Congress of the Vascular Access Society, Istanbul – Turkey, May 5-7, 2011.
- **TWO TYPE SYNCHRONOUS COLONIC ADENOCARCINOMA WITH APPENDICEAL CARCINOID**  
[http://www.eejss.com/journal\\_issue.aspx?issue\\_id=8](http://www.eejss.com/journal_issue.aspx?issue_id=8). European Journal of Surgical Cases.  
<http://www.eejss.com/>.
- **New Techniques in Anal Fistula Management.** Ann Colorectal Res. 2014 May; 2(1): e17769.  
Published online 2014 April 29.
- **Correlation between CRP and early failure of arteriovenous fistula (AVF), Morteza Khavanin Zadeh\*1, Saman Mohammadipour2, Zahra Omrani3, Medical Journal of the Islamic Republic of Iran (MJIRI), MJIRI, Vol. <http://mjiri.iums.ac.ir> 29.219. 8 June 2015**

- A Late Presentation of Spontaneous Bladder Rupture During Labor ,A. Farahzadi a, S. Mohammadipour b,\* Urology Case Reports 8 (2016) 24-25 ,<http://dx.doi.org/10.1016/j.eucr.2016.05.007>,
- ChitoHem hemostatic powder compared with electrocautery anorectal surgery: A randomized controlled trial, Journal of Integrative Cardiology, J Integr Cardiol, 2016, doi: 10.15761/JIC.1000206  
Volume 3(2): 1-3

#### Publications in Farsi

- بررسی ارتباط بین بالابودن CRP و ESR در شکست زودرس در فیستول شریانی وریدی تعبیه شده جهت همودیالیز برای بیماران مراجعه‌کننده به بیمارستان هاشمی‌نژاد در سال

۸۹. vol 20, no. 4 ,2013. Iranian journal of surgery

<http://www.ijs.ir/components4.php?rQV==wHQApDdyFGdz9IZ8BENyAkOkIEduVmchB3XmxHQzAzMApDZJ1WZ0l2XmxHQyATNApDZJ52bpR3Yh9lZ>.

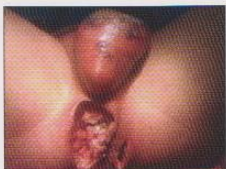- estimating the attitude and tendency of young surgeons to IRAO'S annual meeting  
Mirmalek s.a. m.d , mohammadipour .s md , vol.12, no. 32 2004. Iranian journal of surgery

Orchid id :

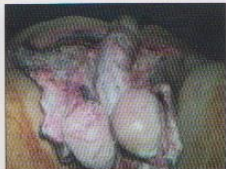

Poster

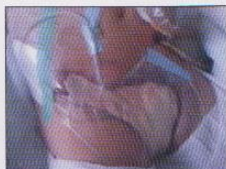20. Necrotizing fasciitis



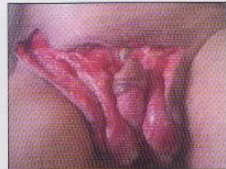Presentation



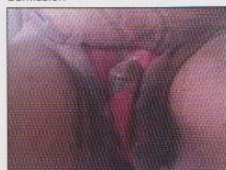The wound after the last debridement (before NPWT) 10 days from admission



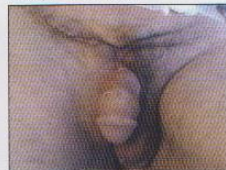During NPWT - 12 days from admission



At the end of NPWT (last dressing) 22 days from admission



After the second stage of the surgical closure 32 days from admission



Post surgery, complete closure 2 months from admission

Date

4th Apr - 14th June 2009

Patient Information

56-year-old male  
C/O Dr. Saman Mohammadi Pour (Assistant General Surgeon), Hazrat Rasool Hospital, Tehran, Iran

Co-Morbidities

None

Wound History

The patient reported to the hospital with fever and perineal pain exhibited 10 days back with abscess in the scrotum, the base of the penis and the perineal was noticed. No similar previous signs and symptoms, except a history of perineal abscess that was treated by incision and drainage 2 years previous to the event. Patient was diagnosed of fourrier gangrene. The wound was treated for 10 days by repeated irrigation and wound debridement (almost 6 sessions). Cystostomy was performed.

NPWT Treatment

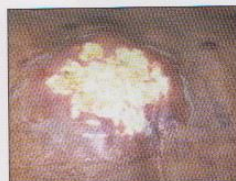
NPWT applied post debridement to promote granulation tissue formation and prepare the wound before the surgical closure. The wound was treated with NPWT device using Smith & Nephew's gauze-based wound dressing as wound filler at -80mmHg. Length of treatment was for 10 days. ACTICOAT<sup>®</sup>, Nanocrystalline Silver dressing was used as a wound contact layer as an antibacterial dressing to control bacterial growth and prevent infection. Dressing changes performed in average every two-three days.

Outcome

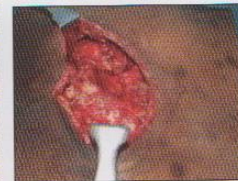Wound bed achieved very good granulation. No signs of infection were noticed and the wound closed surgically in three steps (skin approximation) with complete closure and no signs of dehiscence.

24

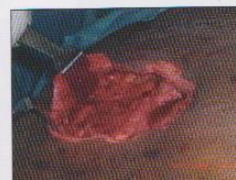21. Carbuncle wound



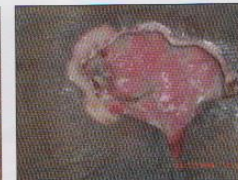Presentation



During debridement



After two dressing changes



Last dressing change

Date

12th - 22nd Dec 2008

Patient Information

50-year-old female  
C/O Dr. Mohan Rangaswamy (Consultant Plastic Surgeon), Welcare Hospital, Dubai, UAE

Co-Morbidities

Diabetes Mellitus (Type I), hypertension and anemia

Wound History

Patient presented with carbuncle enveloped on sacrum area, hard necrotic tissue was presented in the wound with purulent drainage the patient went through surgical debridement before NPWT application. Wound Dimensions: 8 x 8 x 3cm. Wound dimensions including undermining: 13 x 13 x 3cm.

NPWT Treatment

NPWT applied to promote granulation tissue formation, decrease the undermining area in order to do a surgical flap. The wound was treated with NPWT device using Smith & Nephew's RENASYS<sup>®</sup> foam kits at -80mmHg. Length of treatment was for 12 days. Dressing changes performed in average every two days (5 dressing changes).

Outcome

Wound bed achieved good and rapid granulation tissue at this stage then the patient went for further treatment. Wound dimensions at end of treatment: 0.8 x 10 x 2cm. Wound dimensions at end of treatment including undermining area is: 10 x 10 x 3cm.

25

